

Tricks of the Trade

A simple way to take the best mid-treatment orthodontic model

Ortho Update 2024; 17: 179

Diagnostic records are very important in orthodontics. From diagnosis to treatment, planning is executed using proper records, including photographs, models and radiographs. Orthodontic study models have been the 'gold standard' with numerous benefits.¹ Records find their application in patients' education, self-appraisals, medico-legal issues and publications.² The orthodontic model before bonding and after debonding are quite easy to obtain as no brackets are present. On the other hand, taking the mid-treatment model is another issue entirely. One sees tearing of impressions, air bubble formations, missing anatomical landmarks and many more.

Here is a simple method to avoid all these problems and get the best mid-treatment model. The steps are:

- Armamentarium (Figure 1);
- Remove the O-rings, E-chains or any other active component and orthodontic wire;
- Place the separators (light blue) onto the bracket wings (Figure 2);
- Take the alginate impression and pour using white type III dental gypsum (Figure 3);
- The perfect mid-treatment model is ready (Figure 4).

Advantages of this method:

- Easy availability of material;
- Chairside method;
- Easy clinical procedure;
- Less time is needed;
- Cost-effective;
- Better compliance from patients;
- Perfect mid-treatment model procured.

Compliance with Ethical Standards

Conflict of Interest: The authors declare that they have no conflict of interest.

Informed Consent: Informed consent was

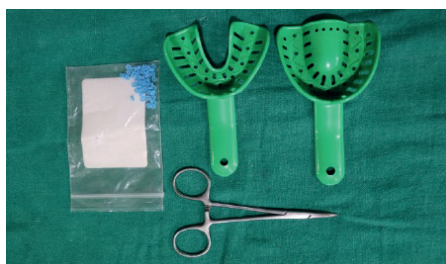

Figure 1. Armamentarium.

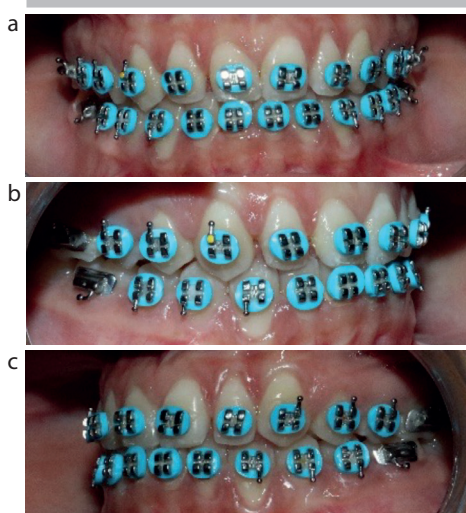


Figure 2. (a-c) Blue separators placed onto the bracket wings.

obtained from all individual participants included in the article.

References

1. Qazi SH, Khurram MS, Hassan M *et al*. Orthodontic record keeping: a study. *Pakistan Oral Dent J* 2010; **30**: 432–435.
2. Arshad F, Narendranath V, Sarala KS. Knowledge and practice of orthodontic record keeping – a clinical audit. *Ann Int Med Dent Res* 2022; **8**: 45–56. <https://doi.org/10.53339/aimdr.2022.8.5.7>

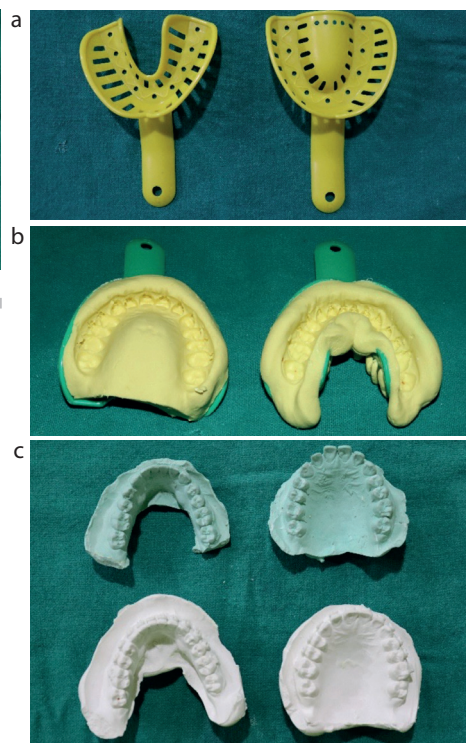


Figure 3. (a-c) Impressions.

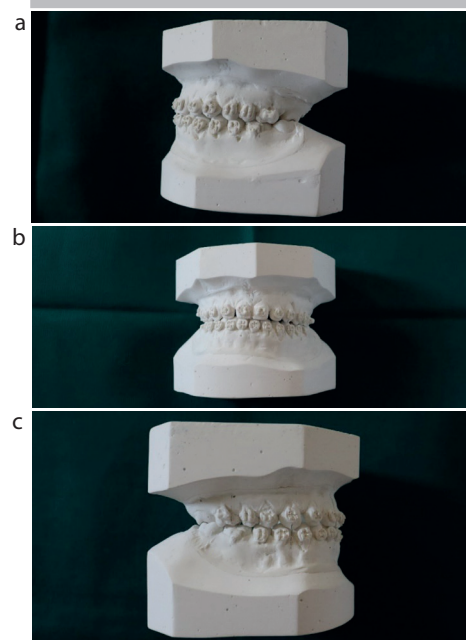


Figure 4. (a-c) Completed mid-treatment model.

Anusha Hegde, BDS, MDS, Assistant Professor, Department of Orthodontics and Dentofacial Orthopedics; **Apurba Gupta**, BDS, MDS, Assistant Professor, Department of Orthodontics and Dentofacial Orthopedics; **Roopak D Naik**, BDS, MDS, Professor and Head, Department of Orthodontics and Dentofacial Orthopedics; SDM College of Dental Sciences and Research Hospital, constituent unit of Sri Dharmastha Manjunatheswara University, Sattur, Dharwad, Karnataka, India.
email: anu011092@gmail.com